Journal of Surgical Oncology 2011;103:362–368

REVIEW

Accelerated Partial Breast Irradiation

PETER D. BEITSCH, MD, FACS,[1]* SIMONA F. SHAITELMAN, MD, EDM,[2] AND FRANK A. VICINI, MD[2]
[1]Dallas Breast Center, Dallas, Texas
[2]Department of Radiation Oncology, William Beaumont Hospital, Royal Oak, Michigan

Whole breast irradiation (WBI) is the standard after breast conservation surgery. However, WBI in selected patients has been questioned. Accelerated partial breast irradiation (APBI) focuses treatment on the lumpectomy bed. Many modalities of delivering APBI have been developed: multicatheter interstitial brachytherapy, MammoSite balloon catheter, single insertion multicatheter devices, three-dimensional conformal external-beam radiation therapy and intraoperative techniques. Numerous studies of APBI have demonstrated excellent local control and cosmetic outcomes in early-stage breast cancer patients.
J. Surg. Oncol. 2011;103:362–368. © 2011 Wiley-Liss, Inc.

KEY WORDS: APBI; radiation; early breast cancer

INTRODUCTION

Multiple prospective, randomized controlled trials with follow-up exceeding 20 years have confirmed the equivalence of lumpectomy + whole breast irradiation (WBI) to modified radical mastectomy, with respect to local control, disease-free survival, and overall survival [1–3]. Breast-conserving therapy (BCT) has become an acceptable option for many patients.

The WBI of standard BCT typically lasts 6–7 weeks with daily (Monday through Friday) post-lumpectomy radiation treatments delivering a dose of 45–50 Gy to the whole breast. This is often followed by a boost to the tumor bed region of another 10 Gy [4]. This type of radiation therapy is well-tolerated, with excellent rates of local control and good cosmesis. Indeed, post-operative adjuvant WBI has been shown to significantly improve long-term overall survival in some subsets of patients [5]. Nevertheless, there are data to suggest that WBI may not be needed in all instances. Analysis of failure patterns after BCT utilizing WBI has demonstrated that a majority (44–86%) of ipsilateral breast tumor recurrences (IBTR) develop in close proximity to the lumpectomy bed [6–9]. In fact, some data suggest that the rate of development of elsewhere recurrences (cancers occurring outside the area of the original cancer and most likely representing a distinct second primary) in the treated ipsilateral breast does not appear to be significantly different from that observed after lumpectomy alone (without WBI) or from the rate of development of contralateral breast failures [6–9]. These data suggest that WBI only treats residual cancer near the lumpectomy cavity and that WBI may not be needed in some subsets of patients.

The rates of BCT vary widely in this country and are dependent on many factors including surgeon preference, socioeconomic status, race, geographical location, surgeon volume, hospital volume, surgical specialization, and date of analysis. It is estimated that anywhere from 35% to 81% of patients eligible for BCT actually receive it [10–13]. In spite of higher local recurrence rates, up to 30% of women treated with lumpectomy never receive adjuvant radiation therapy [14–18]. Many logistical issues may contribute to patients not receiving their prescribed adjuvant radiation therapy, including (1) the lengthy 5- to 7-week course of adjuvant radiation, (2) distance from a radiation treatment facility, (3) lack of transportation, (4) poor ambulatory status, and (5) a paucity of social support [19]. These factors have been found to disproportionately affect patients of lower socioeconomic status, whose rates of BCT lag significantly below the national average [20].

Accelerated partial breast irradiation (APBI) is an alternative way to deliver localized RT to the area of the breast at highest risk of recurrence over a shortened period of time in appropriately selected patients (Table I) [21–24]. Preliminary studies show similar rates of local tumor control with this modality of treatment. This may lead to more breast conservation and better utilization of adjuvant radiation therapy. The most common modalities of APBI will be discussed in some depth.

MULTICATHETER INTERSTITIAL BRACHTHERAPY

Multicatheter interstitial brachytherapy (MIB) is the APBI technique with the longest follow-up and most mature data supporting APBI. MIB requires the placement of 10–20 catheters entirely through the breast surrounding the lumpectomy cavity (Fig. 1). This large number of catheters allows for a very precise treatment plan that will deliver a homogeneous radiation dose to the tumor bed and a defined margin (typically 1–3 cm). Following this, low dose rate (Iodine-125) or high-dose rate (Iridium-192) radioactive sources are temporarily afterloaded into each catheter at precise locations along the catheter for a specified amount of time to deliver the prescribed dose of radiation to the targeted breast tissue.

MIB was initially developed as a technique to deliver a lumpectomy cavity boost after WBI; however it was subsequently adapted as a monotherapy form of APBI in selected patients. At least eight phase 2 or 3 studies with the use of MIB have been reported with up to 10 years of follow-up. These studies have shown that in appropriately selected patients, MIB can provide local control rates similar to those reported with WBI with acceptable cosmesis.

Robert Kuske, MD and his group at the Oschner Clinic (New Orleans, LA) were among the first in the United States to evaluate

*Correspondence to: Peter D. Beitsch, MD, FACS, 7777 Forest Lane, Suite C760, Dallas, TX 75230. Fax: 972-566-2312
E-mail: beitsch@aol.com

Received 28 May 2010; Accepted 21 September 2010

DOI 10.1002/jso.21785

Published online in Wiley Online Library (wileyonlinelibrary.com).

© 2011 Wiley-Liss, Inc.

TABLE I. Recommended Patient Selection for Accelerated Partial Breast Irradiation

Organization	Patient age (years)	Tumor size (cm)	Histology	LN status	Margins
ABS [21]	≥50	≤3	Infiltrating ductal carcinoma	Negative (by sentinel lymph node or axillary dissection)	Negative (at inked margin)
ASBS [22]	≥45	≤2	Invasive ductal carcinoma or ductal carcinoma in situ	Negative (by sentinel lymph node or axillary dissection)	Negative (>2 mm)
NASBP B-39/RTOG-0413 [23]	≥18	≤3	Invasive ductal carcinoma and ductal carcinoma in situ	Allows for 0–3 nodes involved (with negative sentinel lymph node or >6 nodes sampled)	Negative (at inked margin)
ASTRO: suitable patients outside of a clinical trial [24]	≥60	≤2	Invasive ductal ca or other favorable subtypes (mucinous, tubular, and colloid)	Negative (by sentinel lymph node or axillary dissection)	Negative (>2 mm)

MIB as part of BCT. Fifty patients with 51 breast cancers with invasive or in situ tumors less than 4 cm, negative surgical margins, and 0–3 positive axillary lymph nodes were implanted and treated either with low- or high-dose rate brachytherapy. At a median follow-up of 75 months, they reported a crude ipsilateral breast tumor recurrence rate of 2% [25]. In addition, the authors retrospectively compared these patients with a selected case-controlled cohort of patients treated with WBI. This analysis revealed no significant difference in the rates of ipsilateral breast tumor recurrence, locoregional failure, or good to excellent cosmesis rates.

The William Beaumont Hospital group led by Frank Vicini, MD has reported on the largest series of MIB-treated patients with the longest reported follow-up [26]. This study had 199 patients older than 40 years of age with invasive tumors less than 3.0 cm, negative margins >2 mm, and negative axillary lymph node sampling. They were implanted with multiple interstitial catheters and treated with either low- or high-dose rate brachytherapy. A matched-paired analysis of these MIB patients with patients treated with WBI at the same institution revealed an equivalent rate of 10-year actuarial ipsilateral breast tumor recurrences of 5%. Cosmesis was good to excellent results in 98% of the patients followed for a minimum of 10 years [27].

The Radiation Therapy Oncology Group (RTOG) performed a phase 1/2 trial, RTOG 95-17, to evaluate MIB as the sole method of adjuvant radiotherapy after lumpectomy for early-stage breast cancer. Eligibility criteria for this study included patients with invasive tumors less than or equal to 3 cm, disease-free margins, and axillary lymph node sampling demonstrating three or fewer nodes with metastatic disease without extracapsular extension [28]. Patients were treated with either low- or high-dose rate brachytherapy to a dose of 45 Gy over 4.5 days or 34 Gy in 10 fractions over 5 days, respectively. This multi-institutional study demonstrated an acceptable local control rate (4% at 5 years) while demonstrating acceptable acute and late toxicities [29].

Fig. 1. Multicatheter interstitial brachytherapy.

Short-term complications with MIB have been relatively mild and include pain and infection (treated with oral antibiotics and rarely resulting in removal of the catheters). Long-term complications have also been mild and include breast fibrosis and fat necrosis, hypo/hyperpigmentation, and telangiectasias. However, due to the technically challenging nature of this technique and the steep learning curve, MIB is only offered at a few institutions in this country. Also, despite the excellent outcomes, many patients perceive the procedure as potentially excessively painful and often choose a different treatment modality if they are technically able to receive it.

INTRACAVITARY SINGLE LUMEN BRACHYTHERAPY

Despite the encouraging results observed with MIB, the technical challenges and difficulty in training most radiation oncologists in this technique have limited its widespread adoption. Just as the early studies of MIB were being published, Proxima Corporation developed an intracavitary (within the lumpectomy cavity) device—the MammoSite breast brachytherapy applicator. It was cleared for clinical use by the United States Food and Drug Administration (FDA) in May 2002. Since that time, the MammoSite has become the most widely used form of APBI; it has been implanted in more than 60,000 women to date, ascribed in large part to its ease of use.

The MammoSite consists of a single lumen breast brachytherapy balloon catheter that is inserted into the lumpectomy cavity. The catheter is typically placed in the physician's office after the pathology is back to insure negative margins and nodes although it is occasionally placed at the time of lumpectomy in selected patients (Fig. 2). A small skin nick lateral to the lumpectomy incision is made and under ultrasound guidance a trocar is used to make a track to the lumpectomy cavity. The MammoSite balloon is then inserted through the skin, through the track and into the lumpectomy cavity where the balloon is then inflated with saline and radiographic contrast. Positioning is then assessed for adequate skin spacing (optimally >5–7 mm) and conformance of the balloon surface to the lumpectomy cavity. Typically the patient then undergoes a CT scan and this is used to

10969098, 2011, 4, Downloaded from https://onlinelibrary.wiley.com/doi/10.1002/jso.21785 by George Mason University, Wiley Online Library on [12/03/2026]. See the Terms and Conditions (https://onlinelibrary.wiley.com/terms-and-conditions) on Wiley Online Library for rules of use; OA articles are governed by the applicable Creative Commons License

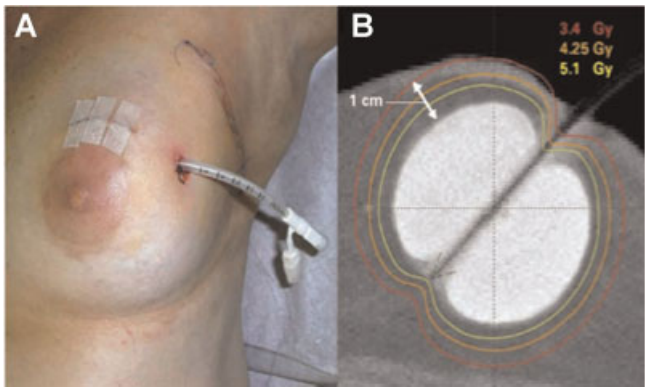

Fig. 2. MammoSite in breast and treatment plan.

create a treatment plan (Fig. 2). A high-dose rate remote afterloading device is used to temporarily deliver an Iridium-192 radioactive source in the center of the balloon for a precise amount of time to deliver a targeted dose of radiation to the breast tissue immediately surrounding the balloon surface (i.e., the lumpectomy margins). A total dose of 34 Gy is delivered over 10 fractions in 5 days (3.4 Gy per treatment and 2 treatments per day separated by 6 hr). At the conclusion of treatment, the MammoSite balloon is deflated and the catheter removed.

Following the FDA clearance of the MammoSite device in May 2002, Proxima started a registry trial of MammoSite balloon usage focusing on short-term complications. In November 2003, The American Society of Breast Surgeons (ASBS) assumed management of the MammoSite Breast Brachytherapy Registry Trial with the intention of gathering both short and long term follow up data. A total of 1,440 patients (with 1,449 cancers) were enrolled until accrual was closed in July 2004. At a median follow-up of 54 months, a 5-year actuarial rate of ipsilateral breast tumor recurrence was 3.8% [30,31]. Cosmesis was considered good or excellent in 90.4% of patients at 48 months [32]. A subset analysis of 194 patients with ductal carcinoma in situ (DCIS) demonstrated an actuarial isolated ipsilateral breast failure rate of 3.4% at 5 years with good to excellent cosmesis in 92% of patients at 60 months [33].

Additionally, Cuttino et al. [34] has reported on a retrospective, multi-institutional experience with the MammoSite brachytherapy device. Patient eligibility criteria included tumors less than 3 cm, negative surgical margins, and no evidence of multicentricity. At a median follow-up for 24 months, of the 483 patients treated, 1.2% experienced an in-breast failure, with two-thirds of these occurring remote from the lumpectomy site (elsewhere failure). Cosmetic results were assessed as good to excellent in 91% of patients.

Preliminary results of a multi-institutional phase 2 study to evaluate the MammoSite balloon device as a modality to deliver APBI in patients with pure DCIS have been presented [36]. One hundred patients from 12 institutions enrolled patients 45 years of age or older, with unicentric, pure DCIS, mammographic lesions of 3 cm or less, negative margins (at least 1 mm in size), and final pathology demonstrating 5 cm or less of tumor. With a median follow-up of 9.5 months, two patients were diagnosed with an ipsilateral breast tumor recurrence (one a true recurrence/marginal miss and the other an elsewhere failure). Cosmetic results were good to excellent in 98% of patients.

In spite of these overall promising results, the MammoSite brachytherapy device has stringent requirements limiting its clinical applicability—more so than MIB. For example, adequate skin spacing and conformance of the MammoSite balloon to the lumpectomy cavity limit the number of patients that can be treated with this technique. As mentioned above, a balloon surface to skin distance is recommended to be at least 5–7 mm, in order to minimize skin dose and to optimize cosmetic results. Similarly, acceptable conformance of the device inside an irregularly shaped lumpectomy cavity is not always possible. If the MammoSite does not meet the specified criteria (seen in up to 9% of those patients in the ASBS trial), it needs to be explanted, following which patients may elect alternative forms of APBI or WBI. These two factors are rarely limitations for MIB.

INTRACAVITARY MULTI-LUMEN BRACHYTHERAPY

Due to the constraints of the single lumen MammoSite balloon catheter, several companies as well as the corporation that manufactures MammoSite (currently Hologic Corporation) have developed single insertion multi-catheter devices. The multi-lumen MammoSite ML and the Contura (SenoRx, Irvine, CA) are both balloon-based technology with multiple lumens within a balloon device (Figs. 3 and 4). They are inserted through a lateral skin nick and inflated similarly to the original MammoSite balloon. An alternative strategy without a balloon is the SAVI device (Cianna, Aliso Viejo, CA) consists of a bundle of catheters that are inserted through a single skin nick and then deployed outward into an elliptical shape (Fig. 5).

Multiple catheters allow for greater flexibility in treatment planning and dose delivery. This allows a narrower skin to balloon distance since the catheters nearest the skin can be loaded to minimize the dose to the skin. This also applies to chest wall, heart and lung doses posteriorly. Conformance of the balloon to the cavity walls is also no longer an issue as any asymmetry can be compensated for in the treatment plan. These multicatheter devices should allow a broader group of women to be treated with brachytherapy.

THREE-DIMENSIONAL CONFORMAL EXTERNAL-BEAM RADIATION THERAPY

The most recently developed technique for the delivery of APBI is that of three-dimensional conformal external-beam radiation therapy

Fig. 3. MammoSite ML.

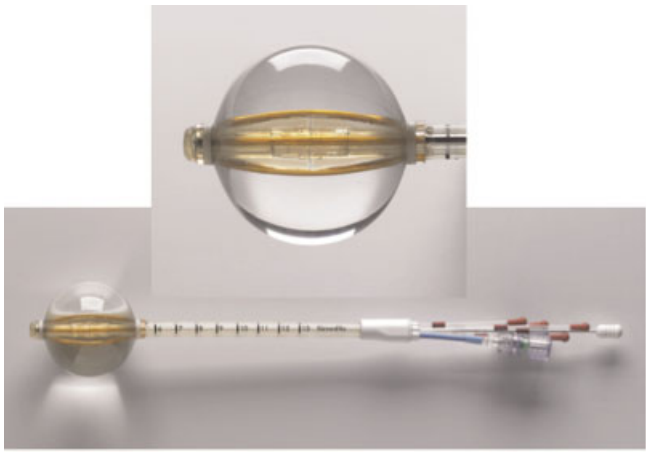

Fig. 4. Contura multicatheter device.

10969098, 2011, 4, Downloaded from https://onlinelibrary.wiley.com/doi/10.1002/jso.21785 by George Mason University, Wiley Online Library on [12/03/2026]. See the Terms and Conditions (https://onlinelibrary.wiley.com/terms-and-conditions) on Wiley Online Library for rules of use; OA articles are governed by the applicable Creative Commons License

Fig. 5. SAVI multi-catheter device.

(3D-CRT). This technique does not require the insertion of any device into the breast and instead uses a linear accelerator. This technique relies upon the delivery of external-beam radiation to a clinical target volume (tumor bed plus 10–15 mm) with an additional margin added (generally 5–10 mm) to account for treatment set-up error and patient motion [37]. In general, three to five beams are used, with patients treated in the supine or prone position (Fig. 6). Compared with other modalities, 3D-CRT is the least studied APBI technique with respect to length of follow-up time and the numbers of patients treated. However, given its relative ease of implementation, there is a growing body of data to validate this form of delivery.

The group at William Beaumont Hospital (Royal Oak, MI) has been among the first to publish data on their experiences using 3D-CRT to deliver APBI. Ninety-four patients with invasive tumors less than or equal to 3 cm, disease-free margins, and axillary lymph node sampling demonstrating three or fewer nodes with metastatic disease without extracapsular extension were treated with 3D-CRT to a dose of 34 or 38.5 Gy in 10 fractions over 5 consecutive days [37]. Now with a median follow-up of 4.2 years, one local recurrence has been seen, yielding a 4-year actuarial ipsilateral breast failure rate of 1.1%. Among patients who had at least 48 months of follow-up, cosmetic assessment was rated as good or excellent in 89%.

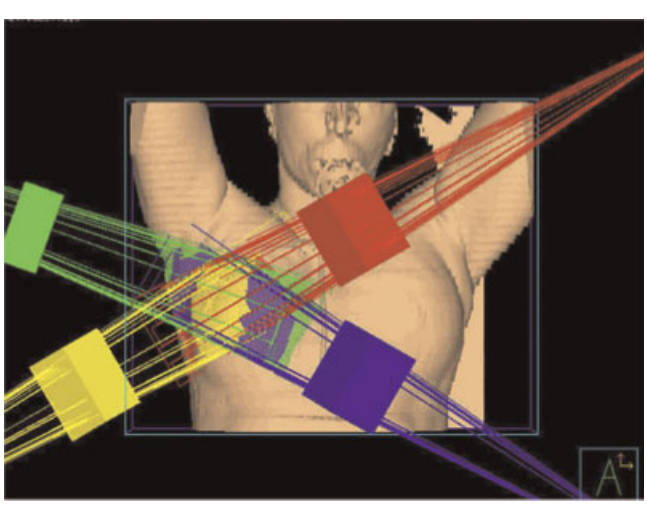

Fig. 6. 3D conformal treatment plan.

Researchers at New York University have pioneered a slightly different approach to the delivery of 3D-CRT, in which patients are treated in the prone position, in an effort to minimize radiation dose to the heart and lung [39]. Seventy-eight patients with stage I breast cancer were treated with 30 Gy (6 Gy $\times$ five fractions) over ten days. At a median follow-up of 28 months, zero patients experienced a recurrence of disease with 92% of patients describing their cosmetic outcome as good to excellent.

Finally, the RTOG conducted a phase I/II trial to evaluate the feasibility of the reproducibility in APBI delivered via 3D-CRT, RTOG 0319 [39]. Fifty-eight patients with stage I or II invasive carcinoma with an index lesion $\leq$3 cm, negative surgical margins, and up to three positive axillary lymph nodes were enrolled. Treatment was a dose of 38.5 Gy in 3.85 Gy/fraction delivered twice daily for 5 days. A total of four cases were cited as having major variations in treatment plans, and it was concluded that 3D-CRT was technically feasible and reproducible in a multi-institutional trial. The secondary endpoint of this trial was efficacy of treatment; at a median follow-up of 4.5 years, the 4-year estimate of ipsilateral breast failure was 6%, with 4% within the treatment field [40]. There were two grade 3 toxicities (4%), both of which involved the skin. Cosmesis has yet to be reported.

3D-CRT offers many advantages over both multicatheter interstitial and intracavitary brachytherapy. First, 3D-CRT is a non-invasive mode of delivering radiation, thereby mitigating the need for additional invasive procedures. Second, the vast majority of radiation oncologists are familiar with the techniques required to deliver linear accelerator-based treatments. Finally, radiation facilities capable of delivering 3D-CRT are far more prevalent than those providing brachytherapy, allowing for greater access for patients. However, 3D-CRT carries the concomitant disadvantages of delivering radiation (all be it low doses) to adjacent critical organs (i.e., heart and lung) and to normal breast tissue in order to account for patient motion and treatment set-up uncertainty.

ALTERNATIVE MODALITIES OF APBI

Other less prevalent modalities of delivering APBI are currently being evaluated, each with its particular limitations. For example, single fraction intraoperative radiation therapy (Figs. 7 and 8) has been utilized in the delivery of monotherapy and boost radiation at the time of lumpectomy in the form of low energy X-rays or electrons [41–43]. Investigated primarily in Europe, data suggest acceptable early recurrence rates, cosmesis, and toxicities. Advantages of intraoperative RT include the delivery of radiation precisely to the operative bed at the time of surgery, thereby minimizing the probability of missing the appropriate treatment area, allowing shielding of critical

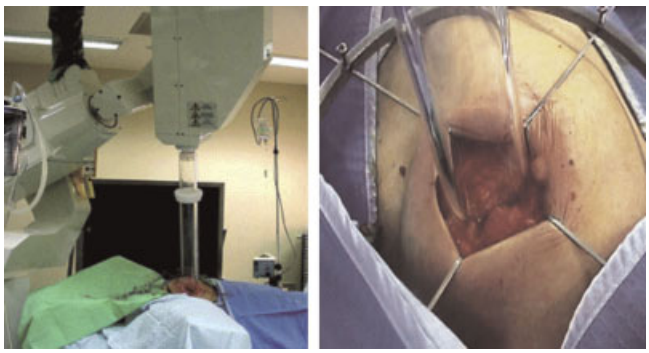

Fig. 7. Intraoperative linear accelerator and collimator in lumpectomy cavity.

10969098, 2011, 4, Downloaded from https://onlinelibrary.wiley.com/doi/10.1002/jso.21785 by George Mason University, Wiley Online Library on [12/03/2026]. See the Terms and Conditions (https://onlinelibrary.wiley.com/terms-and-conditions) on Wiley Online Library for rules of use; OA articles are governed by the applicable Creative Commons License

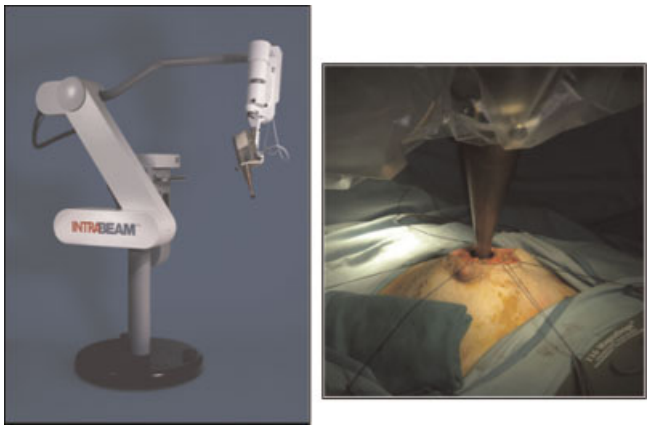

Fig. 8. Intraoperative IntraBeam source and collimator in lumpectomy cavity.

structures, and in the case of low energy X-rays, enabling the delivery of radiation in a standard operating room. However, there are potential problems with intraoperative radiation including delivery of radiation before final pathological confirmation of the lumpectomy margin and lymph node status and the unknown long-term effects of a single high dose of radiation to breast tissue. Currently there is limited availability of this type of radiation therapy.

Permanent seed implantation has also been explored as a method for delivering APBI. A single institution phase I/II trial delivering partial breast irradiation with palladium-103 permanent seed implantation has been reported [44]. Treatment was delivered in a 1 hr procedure that delivered a minimal peripheral dose of 90 Gy to the clinical target volume. At a median follow-up of 32 months, no recurrences were reported. There were 17% of patients who had significant pain after the procedure and 14% had telangiectasias visualized 2 years after the procedure. Given the limited experience with this technique, particularly in comparison to the other forms of brachytherapy, and the high degree of specialization required for its delivery, it remains uncertain if this modality of treatment will be more widely adapted into clinical practice.

Lastly, a variation on the 3D-CRT approach using protons instead of the traditional photons for treatment delivery is being explored. Clinicians at the Harvard-affiliated hospitals have reported their initial dosimetric experience in delivering APBI via protons, a technique that allows for more precise target delivery, thereby markedly reducing the volume of non-target breast tissue that is irradiated [45]. As proton therapy facilities become more widely available, proton usage in the delivery of APBI will likely increase.

THE NSABP-39/RTOG-0413 TRIAL

Despite the encouraging results of numerous phase I and II studies evaluating the efficacy, tolerability, and cosmesis of the various forms of APBI, only one phase 3 study comparing APBI to WBI has been reported to date (Table II) [46]. In order to ascertain the long-term efficacy of APBI, the National Surgical Adjuvant Breast and Bowel Project (NSABP) and the RTOG groups have jointly developed a phase 3 trial: NSABP B-39/RTOG-0413 [23]. This study is a prospective, randomized controlled trial comparing WBI to APBI in women with stage 0, I, or II breast cancer. In order to assess the effectiveness of partial breast irradiation in a variety of clinical scenarios, the inclusion criteria for this trial have been more liberal than those employed in the above-mentioned phase I/II trials. Patients with microscopically negative margins (defined as negative at inked margin, per NSABP criteria), any histology, 0–3 positive lymph nodes, and age of at least 18 years were the originally eligible candidates.

The primary aim of the study is to determine whether APBI provides equivalent local control in the breast compared to conventional WBI in early-stage breast cancer. Secondary end points of the trial include a

TABLE II. Selected Trial Results From Modalities of APBI

APBI technique	Study/institution	Patients, n	Median follow-up, months	Ipsilateral breast tumor recurrence rate, %	Good to excellent cosmesis, %
MIB	King et al. [25], Oschner Clinic (New Orleans, LA)	51	75	2	75
	Antonucci et al. [26], William Beaumont Hospital (Royal Oak, MI)	199	115.2	5	98
	Arthur et al. [28], RTOG 95-17 (multi-institutional)	99	84	4	Not reported (NR)
	Polgár et al. [45]	258	66	MIB: 4.7; WBI: 3.4	MBI: 78; WBI: 63
MammoSite breast brachytherapy applicator	Nelson et al. [30], ASBS Registry Trial	1,400	36.1	2.15	91
	Cuttino et al. [34], (multi-institutional)	483	24	1.2	91
	Benitez et al. [35] (multi-institutional)	100	9.5	2	98
3D-CRT	Chen et al. [37], William Beaumont Hospital	94	50.4	1.1	89
	Wernicke et al. [38], New York University (New York, NY)	78	28	0	92
	Vicini et al. [40], RTOG 03-19 (multi-institutional)	58	54	6	NR

10969098, 2011, 4, Downloaded from https://onlinelibrary.wiley.com/doi/10.1002/jso.21785 by George Mason University, Wiley Online Library on [12/03/2026]. See the Terms and Conditions (https://onlinelibrary.wiley.com/terms-and-conditions) on Wiley Online Library for rules of use; OA articles are governed by the applicable Creative Commons License

comparison of overall survival, recurrence-free survival, and distant disease-free survival in patients receiving APBI versus WBI. Importantly, quality of life measures, including cosmesis, fatigue, and other acute and late treatment-related toxicities, as well as perceived convenience of care, are being assessed.

In this study, patients are randomized to either WBI or APBI delivered via one of three modalities: MIB, the MammoSite, or 3D-CRT, at the discretion of the treating physician and patient preference. Opened in March of 2005, the study has had one of the fastest accruals of any NSABP trial to date, with a total accrual of 3,550 patients as of September 1, 2009 [46]. The initial accrual goal of 3,000 patients has been increased to 4,300, in order to increase statistical power. A relative excess of low-risk patient groups initially enrolled in the study; for this reason, the trial has closed to accrual to women at least 50 years of age with DCIS or with invasive cancer who are also node-negative and/or hormone receptor positive. Definitive results from this trial are years away, but it has the potential to expand the standard of care in breast conservation therapy. If APBI is proven to be as efficacious as WBI, patients with early-stage breast cancer stand to garner significant benefits with regards to convenience.

ASTRO GUIDELINES

In light of the growing number of patients being treated with accelerated partial-breast irradiation outside the framework of a clinical trial, the American Society for Radiation Oncology (ASTRO) Health Services Research Committee convened a task force of experts in breast cancer to develop a consensus statement regarding patient selection criteria for the application of APBI in such a setting [24]. This article outlines three groups of patients, those ''suitable,'' ''cautionary,'' and ''unsuitable,'' for treatment with APBI outside of a clinical trial (Table I). The guidelines represent the compilation of both a systematic literature review and the expert opinions of members of the task force. There is a relative paucity of data supporting the usage of APBI in patients in the ''unsuitable'' and ''cautionary'' categories, and that is why that wording was chosen—not because there is data that concludes that these patients should not be treated with APBI. It is anticipated that as more data emerge, these guidelines will evolve.

CONCLUSIONS

Over the last several decades, breast surgery has become more targeted, going from radical mastectomy to mastectomy to lumpectomy. Regional nodal surgery has gone from complete axillary dissection to just removing the nodes that drain the breast (sentinel node biopsy). Systemic therapy is now more individualized with chemotherapy directed at specific targets on (and within) the breast cancer cell as well as stratifying patients with advanced pathologic analysis of their tumors to see who would and would not benefit from chemotherapy. Similarly radiation therapy in some patients is now able to be focused where it is needed the most—the lumpectomy bed. It can be delivered over a shorter period of time; thereby, improving quality of life and perhaps improving the rate of breast conservation and the delivery of adjuvant radiation therapy. The results of the large, multi-institutional, prospective randomized trial that will define the long-term efficacy of APBI are eagerly anticipated. However, the general adoption of APBI will not wait on these trials just as the widespread adoption of sentinel lymph node biopsy has not waited on the prospective randomized NSABP B32 trial.

REFERENCES

1. Fisher B, Anderson S, Bryant J, et al.: Twenty-year follow-up of a randomized trial comparing total mastectomy, lumpectomy, and lumpectomy plus irradiation for the treatment of invasive breast cancer. N Engl J Med 2002;347:1233–1241.
2. van Dongen JA, Voogd AC, Fentiman IS, et al.: Long-term results of a randomized trial comparing breast-conserving therapy with mastectomy: European Organization for Research and Treatment of Cancer 10801 trial. J Natl Cancer Inst 2000;92:1143–1150.
3. Veronesi U, Cascinelli N, Mariani L, et al.: Twenty-year follow-up of a randomized study comparing breast-conserving surgery with radical mastectomy for early breast cancer. N Engl J Med 2002;347:1227–1232.
4. National Comprehensive Cancer Network NCCN Clinical Practice Guidelines in Oncology Breast Cancer V.1. 2010. Available at http://www.nccn.org/professionals/physician_gls/PDF/breast.pdf. Accessed October 2009.
5. Clarke M, Collins R, Darby S, et al.: Effects of radiotherapy and of differences in the extent of surgery for early breast cancer on local recurrence and 15-year survival: An overview of the randomised trials. Lancet 2005;366:2087–2106.
6. Fowble B, Solin LJ, Schultz DJ, et al.: Breast recurrence following conservative surgery and radiation: Patterns of failure, prognosis, and pathologic findings from mastectomy specimens with implications for treatment. Int J Radiat Oncol Biol Phys 1990;19:833–842.
7. Gage I, Recht A, Gelman R, et al.: Long-term outcome following breast-conserving surgery and radiation therapy. Int J Radiat Oncol Biol Phys 1995;33:245–251.
8. Smith TE, Lee D, Turner BC, et al.: True recurrence vs. new primary ipsilateral breast tumor relapse: An analysis of clinical and pathologic differences and their implications in natural history, prognoses, and therapeutic management. Int J Radiat Oncol Biol Phys 2000;48:1281–1289.
9. Huang E, Buchholz TA, Meric F, et al.: Classifying local disease recurrences after breast conservation therapy based on location and histology: New primary tumors have more favorable outcomes than true local disease recurrences. Cancer 2002;95:2059–2067.
10. Nattinger AB, Gottlieb MS, Veum J, et al.: Geographic variation in the use of breast-conserving treatment for breast cancer. N Engl J Med 1992;326:1102–1107.
11. Morrow M, Bucci C, Rademaker A: Medical contraindications are not a major factor in the underutilization of breast conserving therapy. J Am Coll Surg 1998;186:269–274.
12. Legorreta AP, Liu X, Parker RG: Examining the use of breast-conserving treatment for women with breast cancer in a managed care environment. Am J Clin Oncol 2000;23:438–441.
13. Hiotis K, Ye W, Sposto R, et al.: Predictors of breast conservation therapy: Size is not all that matters. Cancer 2005;103:892–899.
14. Fisher B, Bryant J, Dignam JJ, et al.: Tamoxifen, radiation therapy, or both for prevention of ipsilateral breast tumor recurrence after lumpectomy in women with invasive breast cancers of one centimeter or less. J Clin Oncol 2002;20:4141–4149.
15. Mann BA, Samet JM, Hunt WC, et al.: Changing treatment of breast cancer in New Mexico from 1969 through 1985. JAMA 1988;259:3413–3417.
16. Lazovich DA, White E, Thomas DB, et al.: Underutilization of breast-conserving surgery and radiation therapy among women with stage I or II breast cancer. JAMA 1991;266:3433–3438.
17. Farrow DC, Hunt WC, Samet JM: Geographic variation in the treatment of localized breast cancer. N Engl J Med 1992;326:1097–1101.
18. Ballard-Barbash R, Potosky AL, Harlan LC, et al.: Factors associated with surgical and radiation therapy for early stage breast cancer in older women. J Natl Cancer Inst 1996;88:716–726.
19. Kuerer HM, Julian TB, Strom EA, et al.: Accelerated partial breast irradiation after conservative surgery for breast cancer. Ann Surg 2004;239:338–351.
20. Albain KS, Green SR, Lichter AS, et al.: Influence of patients characteristics, socioeconomic factors, geography, and systemic risk on the use of breast-sparing treatment in women enrolled in adjuvant breast cancer studies: An analysis of two intergroup trials. J Clin Oncol 1996;14:3009–3017.
21. American Brachytherapy Society. Breast Brachytherapy Task Group. February 2007. Available at http://www.americanbrachytherapy.org/resources/abs_breast_brachytherapy_taskgroup.pdf.

10969098, 2011, 4, Downloaded from https://onlinelibrary.wiley.com/doi/10.1002/jso.21785 by George Mason University, Wiley Online Library on [12/03/2026]. See the Terms and Conditions (https://onlinelibrary.wiley.com/terms-and-conditions) on Wiley Online Library for rules of use; OA articles are governed by the applicable Creative Commons License

22. The American Society of Breast Surgeons Consensus Statement for Accelerated Partial Breast Irradiation. http://www.breastsurgeons.org/statements/PDF_Statements/APBI_statement_revised_100708.pdf.
23. NSABP Protocol B-39/RTOG Protocol 0413. Available at http://rtog.org/members/protocols/0413/0413.pdf.
24. Smith BD, Arthur DW, Buchholz TA, et al.: Accelerated partial breast irradiation consensus statement from the American Society for Radiation Oncology (ASTRO). Int J Radiat Oncol Biol Phys 2009;74:987–1001.
25. King TA, Bolton JS, Kuske RR, et al.: Long-term results of wide-field brachytherapy as the sole method of radiation therapy after segmental mastectomy for T(is,1,2) breast cancer. Am J Surg 2000;180:299–304.
26. Antonucci JV, Wallace M, Goldstein NS, et al.: Differences in patterns of failure in patients treated with accelerated partial breast irradiation versus whole-breast irradiation: a matched-pair analysis with 10-year follow-up. Int J Radiat Oncol Biol Phys 2009;74:447–452.
27. Chen PY, Vicini FA, Benitez P, et al.: Long-term cosmetic results and toxicity after accelerated partial breast irradiation: A method of radiation delivery by interstitial brachytherapy for the treatment of early stage breast carcinoma. Cancer 2006;106:991–999.
28. Arthur DW, Winter K, Kuske RR, et al.: A phase II trial of brachytherapy alone after lumpectomy for select breast cancer: Tumor control and survival outcomes of RTOG 95-17. Int J Radiat Oncol Biol Phys 2008;72:467–473.
29. Kuske RR, Winter K, Arthur DW, et al.: Phase II trial of brachytherapy alone after lumpectomy for select breast cancer: Toxicity analysis of RTOG 95-17. Int J Radiat Oncol Biol Phys 2006;65:45–51.
30. Nelson JC, Beitsch PD, Vicini FA, et al.: Four-year clinical update from the American society of breast surgeons MammoSite brachytherapy trial. Am J Surg 2009;98:83–91.
31. Vicini FA, Beitsch P, Quiet C, et al.: Five-year analysis of treatment efficacy and cosmesis by the American Society of Breast Surgeons MammoSite Breast Brachytherapy Registry Trial in patients treated with accelerated partial breast irradiation. Int J Radiat Oncol Biol Phys 2010; May 14 [Epub ahead of print].
32. Goyal S, Khan AJ, Vicini F, et al.: Factors associated with optimal cosmetic results at 36 months in patients treated with accelerated partial breast irradiation (APBI) on the American Society of Breast Surgeons (ASBrS) MammoSite Breast Brachytherapy Trial. Ann Surg Oncol 2009;16:2450–2458.
33. Jeruss JS, Kuerer HM, Beitsch PD, et al.: Update on DCIS Outcomes from the American Society of Breast Surgeons MammoSite® Clinical Registry Trial. Ann Surg Oncol 2010; in press.
34. Cuttino LW, Kesich M, Jenrette JM, et al.: Multi-institutional experience using the Mammosite radiation therapy system in the treatment of early-stage breast cancer: 2-Year results. Int J Radiat Oncol Biol Phys 2008;71:107–114.
35. Benitez PR, Streeter O, Vicini F, et al.: Preliminary results and evaluation of MammoSite balloon brachytherapy for partial breast irradiation for pure ductal carcinoma in situ: A phase II clinical study. Am J Surg 2006;192:427–433.
36. Baglan KL, Sharpe MB, Jaffray D, et al.: Accelerated partial breast irradiation using 3D conformal radiation therapy (3D-CRT). Int J Radiat Oncol Biol Phys 2003;55:302–311.
37. Chen PY, Wallace M, Mitchell C, et al.: Four-year efficacy, cosmesis, and toxicity using three-dimensional conformal external beam radiation therapy to deliver accelerated partial breast irradiation. Int J Radiat Oncol Biol Phys 2010;76:991–997.
38. Wernicke AG, Gidea-Addeo D, Magnolfi C, et al.: External beam partial breast irradiation following breast-conserving surgery: Preliminary results of cosmetic outcome of NYU 00-23. Int J Radiat Oncol Biol Phys 2006;66:S32.
39. Vicini F, Winter K, Straube W, et al.: A phase I/II trial to evaluate three-dimensional conformal radiation therapy confined to the region of the lumpectomy cavity for stage I/II breast carcinoma: Initial report of feasibility and reproducibility of Radiation Therapy Oncology Group (RTOG) study 0319. Int J Radiat Oncol Biol Phys 2005;63:1531–1537.
40. Vicini F, Winter K, Wong J, et al.: Initial efficacy results of RTOG 0319: Three-dimensional conformal radiation therapy (3D-CRT) confined to the region of the lumpectomy cavity for stage i/ ii breast carcinoma. Int J Radiat Oncol Biol Phys 2010; 77: 1120–1127.
41. Holmes DR, Baum M, Joseph D: The TARGIT Trial: Targeted intraoperative radiation therapy versus conventional postoperative whole-breast radiotherapy after breast-conserving surgery for the management of early-stage invasive breast cancer (a trial update). Am J Surg 2007;194:507–510.
42. Intra M, Luini A, Gatti G, et al.: Surgical technique of intraoperative radiation therapy with electrons (ELIOT) in breast cancer: a lesson learned by over 1000 procedures. Surgery 2006;140:467–471.
43. Pignol JP, Rakovitch E, Keller BM, et al.: Tolerance and acceptance results of a Palladium-103 permanent breast seed implant phase I/II study. Int J Radiat Oncol Biol Phys 2009;73:1482–1488.
44. Taghian AG, Kozak KR, Katz A, et al.: Accelerated partial breast irradiation using proton beams: Initial dosimetric experience. Int J Radiat Oncol Biol Phys 2006;65:1404–1410.
45. Polgár C, Fodor J, Major T, et al.: Breast-conserving treatment with partial or whole breast irradiation for low-risk invasive breast carcinoma—5-year results of a randomized trial. Int J Radiat Oncol Biol Phys 2007;69:694–702.
46. Wazer D: Accelerated Partial Breast Irradiation in 2009—For Whom is it Appropriate? Presented at ASTRO's 51st Annual Meeting. Chicago, IL; October 31–November 5, 2009.

10969098, 2011, 4, Downloaded from https://onlinelibrary.wiley.com/doi/10.1002/jso.21785 by George Mason University, Wiley Online Library on [12/03/2026]. See the Terms and Conditions (https://onlinelibrary.wiley.com/terms-and-conditions) on Wiley Online Library for rules of use; OA articles are governed by the applicable Creative Commons License